

INITIAL MANAGEMENT OF PAEDIATRIC ABDOMINAL INJURY

The intra-abdominal contents may extend anteriorly from the nipples to the groin creases and posteriorly from the tips of the scapulae to the gluteal folds. Consequently, intra-abdominal injury frequently co-exists with injuries within the chest and to the pelvis

Within West Yorkshire most children are injured through blunt forces such as motor vehicle collisions, falls and assaults. A much smaller proportion of children are injured through penetrating mechanisms. The management guidance differs between blunt and penetrating mechanisms of injury so these will be considered separately.

Network Referrals

- **Emergency transfers to the Major Trauma Centre should follow the standard pathway. Stabilise, arrange immediate transfer, inform ED consultant at LGI (0113 392 8927 or 392 8908). When time permits contact relevant specialty / ies.**
- The Paediatric surgeon is the first point of call for all abdominal trauma advice.
- The case should be discussed with the on- call Paediatric Surgical Registrar (0113 243 2799 Bleep 1490) or Consultant Paediatric Surgeon at Leeds General Infirmary (switch board 0113 243 2799).

BLUNT INJURY

Clinical assessment

- The patient will be assessed by the trauma team in line with ATLS/APLS principles. Abdominal examination should be included within “C” as a potential site of bleeding. Patients in shock and suspected to have intra-abdominal injury (including at time of pre-alert) need to be discussed at a very early stage with:
 - MTC: the on call Paediatric Surgical Registrar or Consultant (switch board 0113 243 2799).
 - TU: the on call General Surgical Consultant
 - Simultaneously ensure O -ve blood will be available
- MTC: In all cases of massive transfusion protocol activation ensure the interventional radiologist on-call is alerted.
- *Inspection:* abdominal wall bruising e.g. from the seat belt, confirms that the abdomen has been subjected to significant forces and should raise the index of suspicion for injury. New and progressive abdominal distension in a shocked patient clearly suggests exsanguinating intra-abdominal bleeding but a significant volume of intra peritoneal blood can collect without undue distension.
- *Palpation:* Tenderness to palpation is often difficult to interpret especially in children. It may be the result of intra-abdominal organ injury. However, the tenderness elicited may be from local bony injury e.g. fractured lower ribs and / or pelvic fracture. However, both intra-abdominal and bony injury may be present as these fractures are frequently present in patients who also have intra-abdominal injury. Conversely, patients who do have intra-abdominal injury may have little tenderness due to remote but distracting injuries, reduced consciousness (head injury, intoxication, sedating medication, spinal cord injury) or the fact that **a haemoperitoneum causes no signs in about 40% of patients.**
- *Percussion and auscultation* add little to the examination. The presence or absence of bowel sounds has no diagnostic value.

- As clinical assessment may not be reliable, further imaging is justified in most patients where there is a suspicion of abdominal injury.

Investigation

- *Bloods:* An FBC, U&E, clotting, venous gas sample and cross-match (with activation of major transfusion protocol if appropriate) should be taken for all significantly injured patients. A pregnancy test should be taken if relevant. Early amylase measurement does little to guide early management.
- *Ultrasound:* FAST scanning is of limited value in decision making in childhood trauma, but could be performed in patients with suspected intra-abdominal injury. A FAST scan aims to detect fluid in the peritoneal cavity. It cannot distinguish between blood, ascites or spilt intestinal fluid. However, in the context of trauma this is blood until proven otherwise. It is not designed to look directly for solid organ (liver, spleen, kidney) or hollow viscus injury. A normal scan **does not rule out significant intra-abdominal injury and bleeding**. A positive scan must be interpreted in the context of the hemodynamic status of the patient and is not in itself an indication for invasive radiological or surgical intervention. It is most useful as a confirmation of the abdomen as a significant source of bleeding in a patient with deteriorating shock. If a decision has been made to proceed to CT performance of the FAST scan must not delay patient transfer.
- *CT scan:* Unless there is rapid hemodynamic deterioration that requires immediate transfer to theatre, all patients where there is concern for significant injury should undergo a CT scan. An arterial phase CT scan has a high sensitivity and specificity for detecting haemoperitoneum and solid organ (liver, spleen, kidney) injury.
- The presence and site of active bleeding may be identified and so provide a target for embolization treatment. However, this early scan is performed before the inflammatory effects of a viscus perforation have occurred and surprisingly little free gas or fluid may be released. As a result, the initial trauma CT has a much lower diagnostic accuracy for hollow viscus injury. Similarly, fresh pancreatic injury can be difficult to detect on the initial trauma CT.

Management (see Figure 1)

- **The guidance below covers expected management at the Major Trauma Centre. At a Trauma Unit management may be limited by the available resources. When the treatment necessary exceeds the TUs capabilities the patient will require transfer to the MTC. The MTC can be contacted for advice at any time.**
- Patients with unresponsive or transiently responding shock and considered to have ongoing intra-abdominal bleeding require rapid transfer to theatre for laparotomy and any other surgery required to control bleeding e.g. pelvic stabilization, thoracotomy etc. Evidence for an intra-abdominal source includes mechanism of injury, progressive abdominal distension and grossly positive FAST scan. Other causes of severe shock need to be considered e.g. bleeding (chest, pelvis, limbs, bleeding from wounds), tension pneumothorax, cardiac tamponade and cardiac contusion or infarction (rare).
- Patients whose shock is not rapidly deteriorating should have a trauma CT scan.
- Patients with radiological evidence of ongoing bleeding from solid organs (spleen, kidney, liver) must be discussed with the Consultant Paediatric Surgeon and Consultant Interventional Radiologist. These senior decision makers must then decide, based on the patient's hemodynamic status, constellation of injuries and physiological reserve, whether the patient would benefit from minimally invasive embolization after some delay to mobilize personnel compared with proceeding immediately to theatre for more rapid but more invasive surgical hemorrhage control.
 - Patients with radiological evidence of pseudoaneurysm rather than free, active bleeding from the spleen, liver or kidney must be discussed with the Consultant Paediatric Surgeon and Consultant Interventional Radiologist with a view to angio-embolisation. Angio-embolisation of splenic pseudoaneurysms is particularly associated with an increased success of non-operative management.
 - Patients with solid organ (spleen, liver, kidney) injury but no evidence of ongoing bleeding or pseudoaneurysm must be discussed with the Consultant Paediatric Surgeon. Non-operative management can usually be commenced. The patient

must be adequately resuscitated to correct hypoperfusion. In a minority of patients with the expected increase in perfusion pressure, bleeding may recur.

- During non-operative treatment regular clinical examinations and hemoglobin measurements must be undertaken. Regular observations should be performed with calculation and recording of a paediatric physiological warning score. If re-bleeding is suspected (progressive shock and / or falling hemoglobin) transfer to theatre or further CT angiography is required. If confirmed, then angio-embolisation or operative control of bleeding is required. Increasing abdominal pain, tenderness, inflammatory markers or deranged liver function tests may be the result of a missed hollow viscus injury, pancreatic injury or a local complication of solid organ injury e.g. biliary peritonitis. Further CT imaging is indicated to attempt to identify the underlying problem.
- Patients with Grade IV or more splenic or hepatic injuries undergoing non-operative management should be considered for angiography as a proportion will reveal significant vascular injury which if treated should reduce the risk of re-bleeding (see Appendix 1 & 2 for injury grading).
- Patients with evidence of hollow viscus injury, mesenteric injury (and so likely ischemic gut) or diaphragmatic injury on the initial trauma CT will almost certainly require laparotomy and should be discussed with the Consultant Paediatric Surgeon.

Figure 1: Management algorithm for blunt abdominal injury

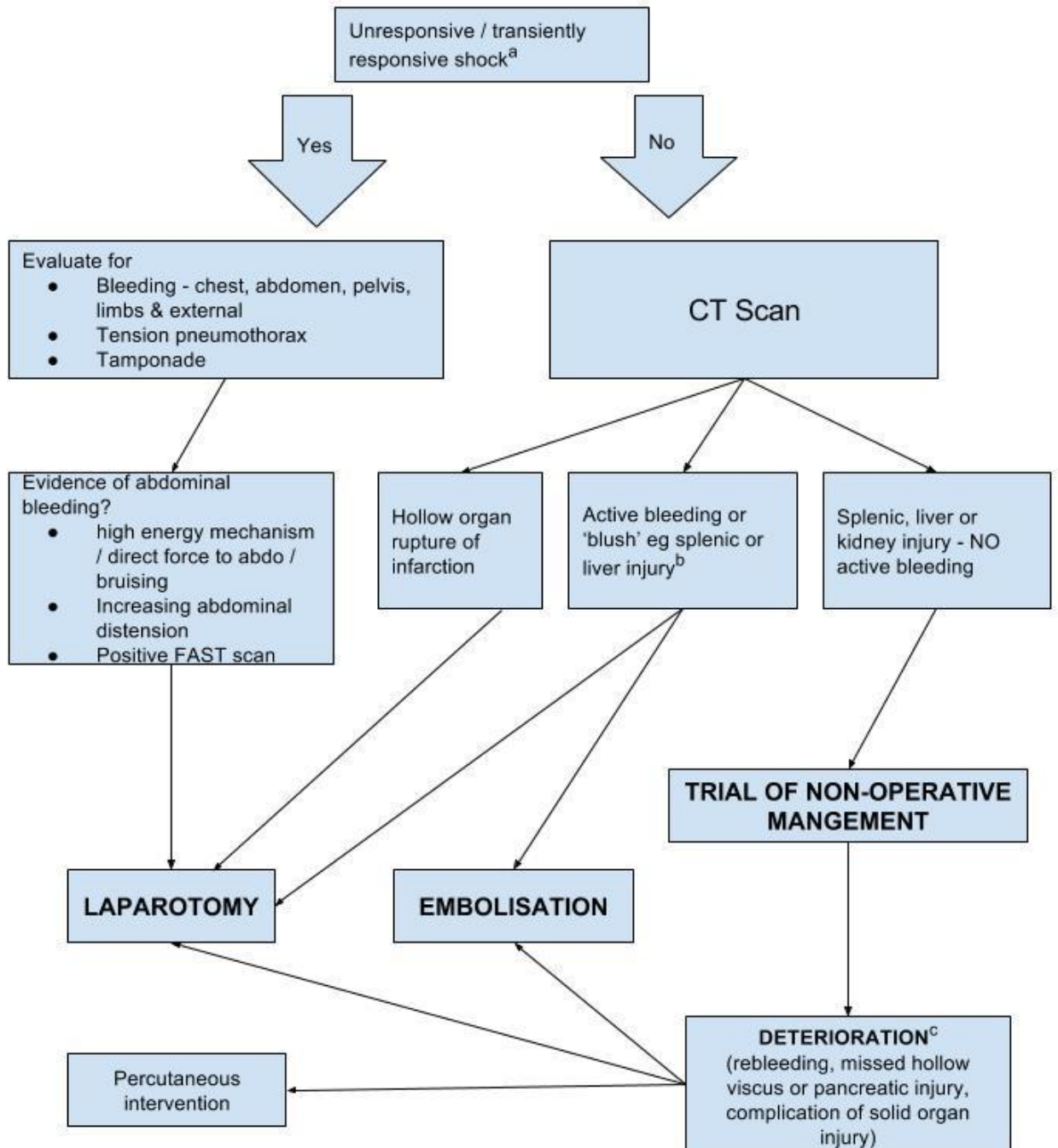


Figure 1 Key

a – Unresponsive or transiently responsive shock is usually due to bleeding. Potential sites (chest, abdomen, pelvis, limbs and external loss) of bleeding should be evaluated. Obstructive / mechanical causes of shock (tension pneumothorax and cardiac tamponade) should also be considered. Rarer causes of shock include myocardial contusion, neurogenic shock, myocardial infarction and air embolus. Non abdominal sources of shock will need intervention in parallel with intra-abdominal assessment and intervention e.g. chest drain, pelvic binder, wound compression etc. Senior decision makers (Consultant Paediatric Surgeon (or equivalent in TU) / Consultant in Emergency Medicine/Consultant Interventional Radiologist) to assess and decide if patient's hemodynamic status is deteriorating too fast to proceed to CT.

b – If bleeding or “blush” reported on CT scan then:

At the MTC: there should be discussion between the consultant Paediatric Surgeon and the consultant interventional radiologist to formulate a management plan.

At a TU: If sufficiently stable the patient should be transferred to the MTC ED as soon as possible. The Paediatric Surgical team should be informed at the **earliest** possible opportunity and the images transferred to permit review by the MTC radiology team.

Evidence of bleeding in to the peritoneal cavity will almost certainly require intervention. Contained blush within a solid organ may not. In an unstable patient the potential for emergency intervention at the TU will vary depending on the resources available. Factors to consider include rate of hemodynamic deterioration, constellation of injuries and physiological reserve. Further guidance on paediatric trauma transfers can be found here:

<http://www.wymtn.com/paediatric-transfers.html>

Embrace can facilitate discussion between multiple clinicians and offer advice on transfer arrangements:

<http://www.sheffieldchildrens.nhs.uk/refer-to-us/embrace/>

c – Patients undergoing a trial of non-operative management require regular clinical assessment and hemoglobin measurements ideally initially within a critical care environment. Evidence of hemodynamic deterioration, falling hemoglobin, increasing abdominal pain or tenderness or rising inflammatory markers requires discussion with the Consultant Paediatric Surgeon. Depending on the rate of deterioration and clinical suspicion, the patient should undergo CT imaging or more rarely emergency transfer to theatre. The CT scan may reveal re-bleeding, missed hollow viscus injury, pancreatic injury or complication of known solid organ injury. Further bleeding may be treated with embolization or surgery determined by hemodynamic deterioration, constellation of injuries and physiological reserve. Missed injuries or complications may require a combination of radiological or surgical intervention depending on the exact diagnosis.

PENETRATING INJURY

Background

- Paediatric penetrating injuries are very uncommon. Within the trauma network, gunshot wounds are very rare but stabbing and impalements do occur. The mechanism of wounding needs to be established as it strongly influences management decisions. Adult patients suffering stab injury are less likely to require laparotomy (25-33%) than those suffering gunshot injury (80-95%) ¹. Note, 55-60% of patients with any stab wound that has entered the peritoneum have hypovolemic shock, peritonitis or bowel / omental evisceration and require a laparotomy. In the remainder, 50% will eventually require operation if observed. The majority of patients with abdominal gunshot wounds have significant intraperitoneal injury and therefore justify laparotomy.
- Clinicians have a responsibility to inform the police if a patient attends the Emergency Department with a knife or gunshot wound after an assault but demographic information should, in the first instance, only be shared with the patient's consent. Reporting is the responsibility of the ED consultant in charge. Further information can be found: [http://www.gmc-uk.org/Confidentiality reporting gunshot.pdf](http://www.gmc-uk.org/Confidentiality%20reporting%20gunshot.pdf) 58821618.pdf

Clinical assessment

- The patient must be assessed by the trauma team in line with ATLS principles. Abdominal examination should be included within "C" as a potential site of bleeding. As with blunt injury, patients in shock with penetrating chest and / or abdominal injury need to be discussed at a very early stage with:
 - MTC: the on-call Consultant Paediatric Surgeon (switch board 0113 2432799).
 - TU: the on-call General Surgical Consultant
 - Simultaneously ensure O -ve blood will be available
 - MTC: In all cases of massive transfusion protocol activation ensure the Interventional Radiologist on-call is alerted.
 - This includes at time of pre-alert from Ambulance Control

- *Inspection:* Anatomically, the intra-abdominal contents may extend anteriorly from the nipples to the groin creases and posteriorly from the scapulae tips to the gluteal folds. Any penetrating wound within this area may produce an intra-peritoneal injury and must be identified. Unless the patient requires an emergency department thoracotomy, the patient must be log rolled to identify all injuries. Particular care should be taken to inspect the axillae and perineum as wounds in these sites can be missed. Skin wounds should be marked with radio opaque markers e.g. closed paper clip taped to anterior wounds and opened paper clip to posterior wounds. Any protruding knife / foreign body must **not** be removed. Remember, new and progressive abdominal distension in a shocked patient clearly suggests exsanguinating intra-abdominal bleeding but a significant volume of intra peritoneal blood can collect without undue distension.
- *Palpation:* Tenderness around the wound is to be expected but progressive pain and tenderness remote from the initial wound suggests intra peritoneal hollow viscus injury. As with blunt injury, the reliability of clinical examination will be reduced with there are remote but distracting injuries or reduced consciousness (head injury, intoxication, sedating medication, spinal cord injury).
- *Percussion and auscultation:* add little to the examination. The presence or absence of bowel sounds has no diagnostic value.

Management of penetrating injuries.

- **The guidance below covers expected management at the Major Trauma Centre. At a Trauma Unit management may be limited by the available resources. When the treatment necessary exceeds the TUs capabilities the patient will require transfer to the MTC. The MTC can be contacted for advice at any time.**

Management of stab wounds (see Figure 2)

- For patients with penetrating injury balanced resuscitation should be utilized unless contraindicated (head injury).

- Patients with unresponsive or transiently responding shock and considered to have on going intra-abdominal bleeding require rapid transfer to theatre for laparotomy and any other surgery required to control bleeding e.g. thoracotomy. Other causes of severe shock need to be considered e.g. bleeding (chest, limbs, bleeding from wounds), tension pneumothorax and cardiac tamponade. Clearly, patients with multiple wounds can have life threatening pathology in more than one body cavity.
- Patients with foreign bodies e.g. knives, protruding from the abdomen require these to be removed in the operating theatre with the abdomen open if there is any concern that they may have entered the peritoneum. Preoperative CT scan is likely to be degraded by artefact but may be considered if findings would influence surgical approach.
- Patients without overt shock but with clinical signs of peritonitis or bowel / omental evisceration require a laparotomy (bowel evisceration is associated with a 75% risk of bowel perforation). A FAST scan has no role in the exclusion of hollow viscus injury. A preoperative CT scan may be undertaken but the trauma scan is poor at detecting fresh hollow organ injury.
- Patients without overt shock but with an unreliable examination e.g. brain injury, spinal cord injury, intoxication or sedating medication, should have further investigation with a CT scan or undergo exploratory laparotomy / laparoscopy.

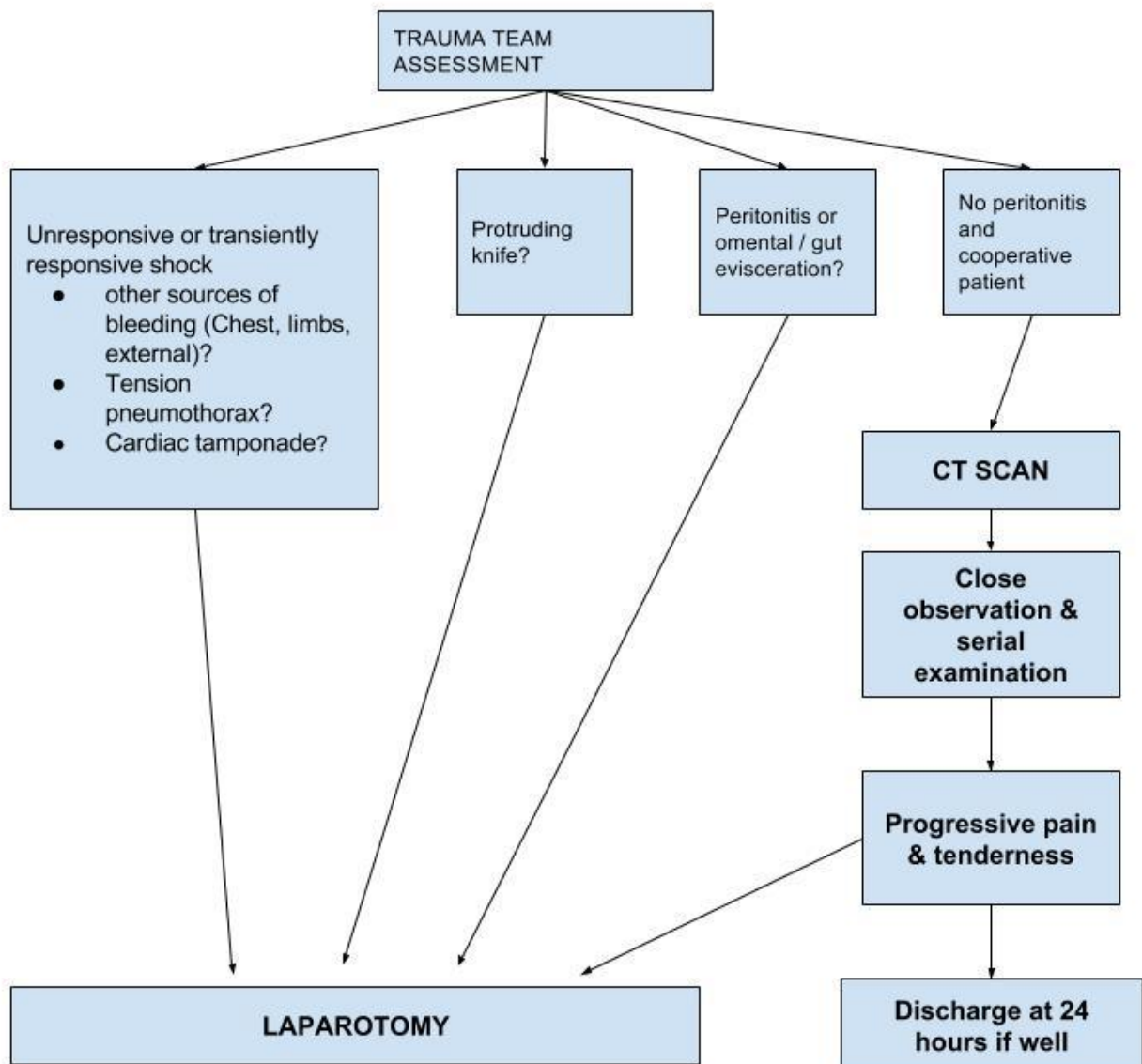
Patients who are conscious, cooperative and can concentrate and with no signs of peritonitis or diffuse abdominal tenderness (away from the wounding site) may be initially managed non-operatively. A CT scan should be performed to help quantify the depth of injury. Repeated / serial examination preferably by the same experienced surgeon should be undertaken. Regular observations should be performed with calculation and recording of a paediatric physiological warning score. At hand over, ideally both surgeons should examine the patient together and agree on the clinical findings. Any injury is likely to reveal itself within 24 hours so after this time, if diet can be reintroduced and abdominal findings are minimal, the patient can be discharged.

- Stab wounds can be classified as anterior (between the anterior axillary lines), flank (between anterior and posterior axillary lines) and posterior (posterior to posterior axillary line). In general, one third of anterior wounds do not penetrate the peritoneum.

One third, penetrate the peritoneum but do not require intervention and the remaining third penetrate the peritoneum and require surgical repair. Anterior abdominal wounds may be explored under local anaesthetic within the emergency department if the child is older and compliant or under a general anaesthetic in theatre. If the wound extends deep to the anterior fascia then the chance of intraperitoneal hollow viscus perforation is increased although not definite. Patients with posterior fascial penetration proceed to theatre to laparotomy / laparoscopy. Hollow viscus injury can be difficult to detect even at laparotomy. Laparoscopic examination to exclude injury is practiced in some high volume centers. Within the Trauma Network exclusion of visceral injury by laparoscopy should only be performed by those with appropriate skills and experience.

- Exploration of flank and posterior wounds is rarely indicated. In the absence of a need for immediate laparotomy (shock or generalized peritonitis), a CT scan helps to determine depth of injury. Oral / rectal / IV contrast enhanced CT may help to exclude retroperitoneal organ injury e.g. colon and should be discussed with the on-call radiologist.
- Thoraco-Abdominal injuries can present a diagnostic dilemma as penetrating wounds between the nipples and costal margin may damage structures within the chest cavity, within the peritoneal cavity and make a hole in the intervening diaphragm.
 - As indicated above, patients with unresponsive or transiently responding shock and considered to have ongoing abdominal or thoracic bleeding require rapid chest drain insertion and transfer to theatre for laparotomy and any other surgery required to control bleeding e.g. thoracotomy.
 - For patients without overt shock, a CT scan will give some indication of the trajectory of the wound although may not detect incised wounds of the diaphragm. If concern regarding diaphragmatic injury persists, then a laparoscopy/laparotomy should be performed. If an injury is detected then the defect should be repaired and visceral injury excluded. Both diaphragmatic repair and exclusion of visceral injury are possible laparoscopically but only by those with appropriate skills and experience.

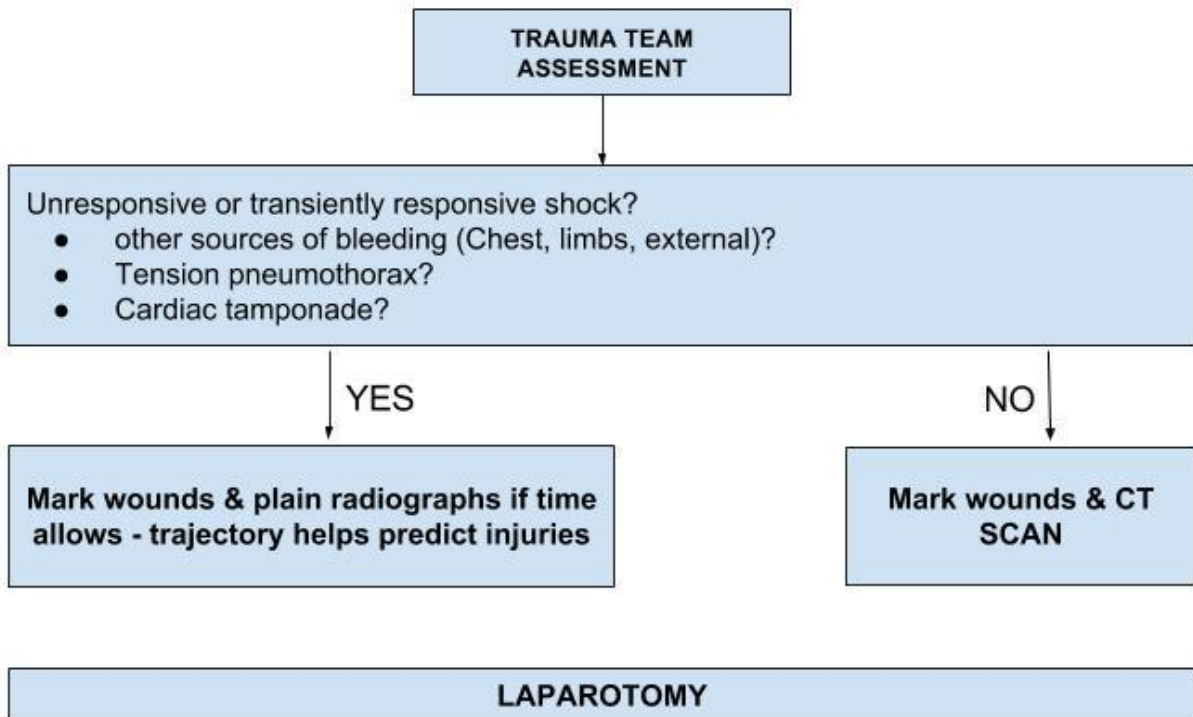
Figure 2: Management algorithm for penetrating stab injury



Management of low velocity (hand gun / shotgun) gunshot wounds (see Figure 3)

- These are extremely rare in the paediatric age range and management should follow adult guidelines.
- Patients with abdominal gunshot wounds have a very high chance of intraperitoneal injury and nearly always justify laparotomy. A few patients suffer tangential wounds where the path of the bullet is subcutaneous and does not penetrate the peritoneum. Plain radiographs (chest & abdo/pelvis) after marking of skin wounds (see above) helps to determine trajectory and is helpful in injury identification and planning the surgical approach. Patients with unresponsive or transiently responding shock require immediate laparotomy. Those without overt shock may undergo a CT scan to guide surgical planning and identify those few patients with tangential injuries. Close range shot gun injuries are locally destructive and likely to penetrate the peritoneum mandating laparotomy. For those delivered at distance, CT scanning may demonstrate pellet penetration deep to peritoneum although scatter may limit image quality.

Figure 3: Management algorithm for gunshot injury



Related issues

Patient advice regarding return to normal activity and return to contact sports

- Advice regarding mobility must also take into account any musculoskeletal & head injuries. There is little data to guide return of activity and the following is a probably a conservative recommendation based on injury grade (see Appendix 1 - 3). However, with regard to solid organ injury (spleen, liver, kidney) recommend:
 - Rest at home = 1 week per grade of injury
 - Avoid contact sports (including horse riding) = 1 month per grade of injury
- For example, a patient with a grade III splenic laceration should be advised to...
 - **Rest at home for 3 weeks** (specifically **not** to be advised to stay in bed, normal gentle activities of daily living should be fine, do not do anything that gets them out of breath)
 - **No contact sport for 3 months.**

Venous Thromboembolic (VTE) prophylaxis in patients with abdominal injury

- Mechanical prophylaxis e.g. TED stockings can be used for all patients where an appropriate size exists, unless precluded by lower limb injury.
- For pubertal / post pubertal children and those with specific thrombosis risk factors pharmacological prophylaxis with a fractionated heparin should be commenced when the risk of further bleeding becomes less than the risk of VTE.
 - Typically, for a patient who has required a laparotomy to arrest bleeding, pharmacological prophylaxis is commenced at 18.00 of the following day as long as the clotting (APTT & INR) has returned to normal.

- There is no evidence that pharmacological prophylaxis reduces the success of non-operative management of blunt liver and splenic injuries. Similarly, pharmacological prophylaxis is commenced at 18.00 of the following day as long as the clotting (APTT & INR) has returned to normal.
- Patients requiring laparotomy for hollow viscus injury rather than bleeding can usually commence post-operative pharmacological prophylaxis at 18.00 on the day of surgery unless there is evidence of coagulopathy.

APPENDIX 1

Liver Injury Scale

The American Association for the Surgery of Trauma (AAST) liver injury grading system for liver trauma is as follows:

Grade I

Haematoma: sub capsular, < 10% surface area

Laceration: capsular tear, < 1cm depth

Grade II

Haematoma: sub capsular, 10 - 50% surface area

Haematoma: intra-parenchymal < 10cm diameter

Laceration: capsular tear, 1 - 3cm depth, < 10cm length

Grade III

Haematoma: sub capsular, > 50% surface area, or ruptured with active bleeding

Haematoma: intra-parenchymal > 10 cm diameter

Laceration: capsular tear, > 3 cm depth

Grade IV

Haematoma: ruptured intra-parenchymal with active bleeding

Laceration: parenchymal disruption involving 25 - 75% hepatic lobes or involves 1-3 Couinaud segments (within one lobe)

Grade V

Laceration: parenchymal disruption involving >75% hepatic lobe or involves > 3 Couinaud segments (within one lobe)

Vascular: juxta-hepatic venous injuries (IVC, major hepatic vein)

Grade VI

Vascular: hepatic avulsion

APPENDIX 2

Splenic injury scale

The American Association for the Surgery of Trauma (AAST) splenic injury grading system is as follows:

Grade I

Subcapsular haematoma <10% of surface area

Capsular laceration <1 cm depth

Grade II

Subcapsular haematoma 10-50% of surface area

Intra-parenchymal haematoma <5 cm in diameter

Laceration 1-3 cm depth not involving trabecular vessels

Grade III

Subcapsular haematoma >50% of surface area or expanding

Intra-parenchymal haematoma >5 cm or expanding

Laceration >3 cm depth or involving trabecular vessels

Ruptured subcapsular or parenchymal haematoma

Grade IV

Laceration involving segmental or hilar vessels with major devascularization (>25% of spleen)

Grade V

Shattered spleen

Hilar vascular injury with devascularised spleen

APPENDIX 3

Renal injury scale

The American Association for the Surgery of Trauma (AAST) renal injury grading system is as follows:

Grade I:

Contusion or non-enlarging sub-capsular haematoma, but no laceration.

Grade II

Superficial laceration <1cm depth and does not involve the collecting system; non expanding peri-renal haematoma.

Grade III

Laceration >1cm, without extension into the renal pelvis or collecting system and with no evidence of urine extravasation.

Grade IV

Laceration extends to renal pelvis or urinary extravasation.

Vascular: injury to main renal artery or vein with contained haemorrhage.

Grade V

Shattered kidney.

Avulsion of renal hilum: devascularisation of kidney due to hilar injury.